

Role of noncontrast magnetic resonance pulmonary imaging in diagnosis of pulmonary embolism

Osama I. Mohammad^a, Ali A. Okab^a, Enas M.M. Sweed^b,
Salwa H. Mohammed Elsaid^a, Mohammed S. Sadek^a

Departments of
^aChest Diseases, ^bRadiology, Faculty of Medicine,
Benha University, Benha, Egypt

Correspondence to Salwa Hassan Mohammed
Elsaid, Msc, Assistant Lecturer of Chest
Diseases, Faculty of Medicine, Benha University,
Benha, Egypt.
Tel: +01147000027;
e-mail: Salwa.has1986@gmail.com

Received: 7 April 2022
Revised: 21 May 2022
Accepted: 23 May 2022
Published: XX XX XXXX

**The Egyptian Journal of Chest Diseases and
Tuberculosis** 2022, XX:XX-XX

Background

Pulmonary embolism (PE) is a serious condition and has a clinical dilemma in diagnosis. Computed tomography pulmonary angiography (CTPA) is a gold standard in its diagnosis, but MRI has proven a good role in PE diagnosis.

Aim

The aim of this work was to evaluate the role of noncontrast magnetic resonance pulmonary angiography (MRPA) imaging in diagnosis of acute PE using CTPA as a gold standard.

Patients and methods

In total, 25 patients with PE confirmed by CTPA were included in this study. All patients underwent computed tomography angiography and noncontrast MRPA on the same day or within three consecutive days. The results were compared and statistically analyzed.

Results

The mean age of the study group was 46.4 ± 13.5 years. Females represent 60% (15/25) and males represent 40% (10/25). The per-vessel sensitivity of noncontrast MRPA reached to about 100% with specificity 100% at the level of the main trunk, right and left main pulmonary arteries down to segmental arteries. The sensitivity for right subsegmental branches was 25% and left subsegmental branches was 33.3%.

Conclusion

The noncontrast MRPA has a reasonable sensitivity and specificity in the diagnosis of PE, especially in major branches. So, it can be used as an alternative to the computed tomography angiography, especially when the computed tomography angiography and the use of gadolinium are contraindicated.

Keywords:

computed tomography angiography, magnetic resonance pulmonary angiography, pulmonary embolism

Egypt J Chest Dis Tuberc 2022, XX:XX-XX
© 2022 The Egyptian Journal of Chest Diseases and Tuberculosis
2090-9950

Introduction

Pulmonary embolism (PE) is a serious condition responsible for significant morbidity and mortality. PE is currently the third leading cause of cardiovascular death worldwide, so, it requires prompt diagnosis and treatment to prevent potentially deadly consequences [1].

The diagnosis of acute PE is considered a clinical dilemma due to a wide spectrum of multiple nonspecific signs and symptoms.

Computed tomography pulmonary angiography (CTPA) is considered the gold standard in diagnosis of PE [2].

The limitations of CTPA include exposure to ionizing radiation and iodinated contrast agent, which carries a risk of allergic reactions and kidney damage in some patients [3].

Magnetic resonance pulmonary imaging (MRPI) is an attractive new method with the advantage of radiation avoidance and contrast avoidance that has no nephrogenic effect and no allergic risk [4].

Aim

The aim of this work was to evaluate the role of noncontrast magnetic resonance pulmonary angiography (MRPA) imaging in diagnosis of acute PE using CTPA as a gold standard.

Patients and methods

Study design: prospective case-control study.

This is an open access journal, and articles are distributed under the terms of the Creative Commons Attribution-NonCommercial-ShareAlike 4.0 License, which allows others to remix, tweak, and build upon the work non-commercially, as long as appropriate credit is given and the new creations are licensed under the identical terms.

Patients: this study included 25 patients with PE confirmed by CTPA from those who attended Chest Department, Benha University Hospital, in the period between August 2019 and August 2021.

Inclusion criteria

Adult patients with clinically evident PE confirmed by CTPA.

Exclusion criteria: patients known to have contraindication for MRI, for example, an implanted magnetizable device, pacemakers, or claustrophobia. Patients clinically unstable.

All patients were subjected to the following:

- (1) Written consent from the patient.
- (2) Full history taking and clinical examination.
- (3) D-dimer.
- (4) Duplex on lower-limb deep veins if indicated.
- (5) ECG.
- (6) Echocardiography.
- (7) Chest radiograph posteroanterior view.
- (8) Arterial blood gas.
- (9) CTPA.
- (10) Noncontrast pulmonary MRI examination on the same day or within three consecutive days of CTPA.
 - (a) Ethical consideration: an approval from an ethical committee in Ain Shams University was obtained before this study was initiated. All participants signed a written informed consent, and patients' privacy was maintained.

Technique of noncontrast magnetic resonance pulmonary angiography examination

- (1) No specific preparation was needed before MRI examination.
- (2) MRI study was performed by using MRI Magnetom Aera 1.5 T scanner (Siemens Company, Erlangen, Germany).
- (3) Patient position: supine with arms elevated.
- (4) Examination time was 30–60 min.

Image interpretation

- (1) The images were transferred to interpretation by senior staff blindly without knowing the result of the previously done CTPA.
- (2) MRPA findings of PE include filling defects, cutting of blood vessel, dilatation of the main pulmonary artery, and caliber change with post-stenotic dilatation [5].
- (3) MRI allows for visualization of PE on pulmonary perfusion images such as areas of reduced, delayed,

or absent blood flow. MR perfusion imaging has a high sensitivity for detecting PE and it is often used in combination with MRPA [6].

- (4) The extension of the PE was recorded.

Results

This study involved 25 patients, their mean age was 46.4 ± 13.5 years. Females represent 60% (15/25) and males represent 40% (10/25) (Table 1).

About risk factors of PE, 48% of patients had deep venous thrombosis (DVT), 36% used oral contraceptive pills, 28% reported immobility, and 8% were intravenous addict and, 8% had malignancy, 60% were overweight and obese (Table 2).

All cases had elevated D-dimer ($\mu\text{g/ml}$) level. Also, 84% (21/25) of patients had echocardiography findings in the form of 40% had mild dilated right ventricle (RV), 24% had tricuspid regurge (TR), and 48% (12/25) had DVT (Table 3).

Table 1 Demographic data of the studied group (N=25)

	n (%)	
Sex		
Male	10 (40)	
Female	15 (60)	
Age (years)	Range	Mean \pm SD
	19–72	46.4 \pm 13.5

Table 2 Risk factors of pulmonary embolism in the studied group

Risk factors	n (%)
Immobility	7 (28)
Oral contraception	9 (36)
DVT*	12 (48)
IV addiction*	2 (8)
Malignancy	2 (8)
BMI \geq 24.9*	15 (60)
Mean \pm SD (range)	25.8 \pm 5.4 (17–35)

*Shows that about 48% of patients had DVT, 36% used OCP, 28% reported immobility, 8% were IV addict, 8% had malignancy, and 60% were overweight and obese, which were statistically highly significant.

Table 3 Investigations of the studied group

Variables	n (%)
D-dimer >0.4 $\mu\text{g/ml}$	25 (100)
Mean \pm SD (range)	1.48 \pm 0.37 (0.65–3)
Echocardiography	
Mild dilated RV*	10 (40)
TR	6 (24)
Duplex lower limbs (DVT)	12 (48)

RV, right ventricle; TR, tricuspid regurge. *Shows the investigations of the studied group. All cases had elevated D-dimer (mcg/ml) level. Also, 84% (21/25) of patients had ECHO findings in the form of 40% had mild dilated RV, 24% had TR and 48% (12/25) had DVT, all of which was statistically highly significant.

Table 4 Noncontrast P-MRI result analysis using computed tomography pulmonary angiography as a gold-standard test

Distribution of pulmonary embolism	CT positive cases [n (%)]	MRI positive cases [n (%)]
Main pulmonary trunk	2 (8)	2 (8)
Right main pulmonary artery	14 (56)	14 (56)
Left main pulmonary artery	12 (48)	12 (48)
Lobar branches	12 (48)	12 (48)
Right upper-lobe segmental arteries	9 (36)	9 (36)
Right middle-lobe segmental arteries	5 (20)	5 (20)
Right lower-lobe segmental arteries	10 (40)	10 (40)
Left upper-lobe segmental arteries	4 (16)	4 (16)
Left lingula segmental arteries	1 (4)	0
Left lower-lobe segmental arteries	10 (40)	10 (40)
Right subsegmental branches	4 (16)	1 (4)
Left subsegmental branches	3 (12)	1 (4)
Cases with pulmonary embolism not detected	0	6 (24)
Total number of thrombi detected	86	80

Table 5 The sensitivity and specificity of noncontrast magnetic resonance pulmonary angiography in pulmonary embolism detection in comparison with computed tomography pulmonary angiography as a standard test

Distribution	Sensitivity%	Specificity %	PPV%	NPV%	Accuracy (efficacy)
Main trunk pulmonary artery	100	100	100	100	100
Right main pulmonary artery	100	100	100	100	100
Left main pulmonary artery	100	100	100	100	100
Lobar branch thrombus	100	100	100	100	100
Right upper-lobe segmental arteries	100	100	100	100	100
Right middle-lobe segmental arteries	100	100	100	100	100
Right lower-lobe segmental arteries	100	100	100	100	100
Left upper-lobe segmental arteries	100	100	100	100	100
Left lingula segmental arteries	Not tested	100	Not tested	96	96
Left lower-lobe segmental arteries	100	100	100	100	100
Right subsegmental branches	25	100	100	87.5	88
Left subsegmental branches	33.3	100	100	91.7	92

NPV, negative predictive value; PPV, positive predictive value.

The PE was more evident involving the right main pulmonary artery as seen in 14 cases. The vessels in each case were analyzed in both contrast-enhanced CTPA and noncontrast MRPA, namely main pulmonary trunk, right and left main posteroanterior divisions, lobar divisions, as well as segmental branches and subsegmental branches. It was found that the results of both noncontrast MRPA and CTPA were the same at the level of pulmonary trunk, right and left main posteroanterior, and right-upper and right-middle lobar arteries. However, MRPA and CTPA were different at the level of lingula, left and right subsegmental arteries. CTPA results were better than MRPA as six thrombi were not detected by MRPA and detected by CTPA (Table 4).

The per-vessel sensitivity of noncontrast MRPA reached to about 100% with specificity 100% at the level of the main trunk, right and left main pulmonary arteries down to segmental arteries. The sensitivity for right subsegmental branches was 25% and left subsegmental branches was 33.3% (Table 5).

Discussion

PE is a serious condition responsible for significant morbidity and mortality. PE is currently the third leading cause of cardiovascular death worldwide, so, it requires prompt diagnosis and treatment to prevent potentially deadly consequences.

CTPA is highly sensitive and specific for the diagnosis of PE. MRI offers a potential alternative to CTPA in the evaluation of the pulmonary vasculature and the diagnosis of PE.

In this study, the patients were randomly selected according to inclusion and exclusion criteria, their mean age was 46.4 ± 13.5 years and 60% of them were females and 40% were males (Table 1).

In another study, 11 patients (five males, six females) were involved with an average age (\pm SD) of 56.6 ± 10.8 years (age range, 45–78 years) diagnosed with acute PE on CTPA [1].

Regarding the risk factors of PE, two-thirds (60%) of the studied group suffered obesity, 48% had DVT, 36% used oral contraceptive pills, 28% reported immobility, 8% were intravenous addicts, and 8% had malignancy (Table 2).

In the study of Sherif *et al.* [7], which involved 21 cases with suspected PE, immobilization was the highest risk factor among the studied group followed by cancer anywhere in the body.

In the current study, there was obvious association between PE and elevated level of D-dimer in all cases. The mean and SD were 1.48 ± 0.37 and the range was 0.65–3 (Table 3).

Also, Sikora-Skrabaka *et al.* [8] found that CTPA should be considered even for patients with low probability of PE when D-dimer values exceed four times the normal level.

According to the echocardiography findings, 40% of the patients with PE had mild dilated RV and 24% with TR. As DVT is one of the main risk factors for PE, 48% of the cases in this study had DVT in the lower limbs (Table 3).

In the current study, PE involved the right main pulmonary artery in 14 cases. The vessels in each case were analyzed in both contrast-enhanced CTPA and noncontrast MRPA, namely main pulmonary trunk, right and left main posteroanterior divisions, lobar divisions, as well as segmental branches and subsegmental branches. It was found that the results of both noncontrast MRPA and CTPA were the same at the level of pulmonary trunk, right and left main posteroanterior, and right-upper and right-middle lobar arteries. However, MRPA and CTPA were different at the level of lingula, left and right

subsegmental arteries. CTPA results were better than MRPA as six thrombi were not detected by MRPA and detected by CTPA (Table 4).

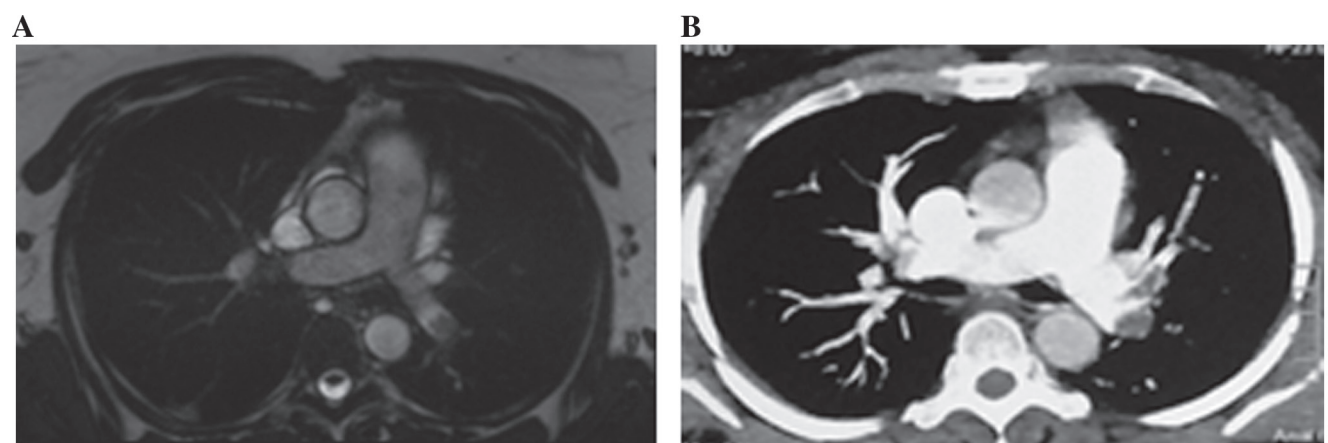
In the current study, the per-vessel sensitivity of noncontrast MRPA reached to about 100% with specificity 100% at the level of the main trunk, right and left main pulmonary arteries down to segmental arteries. The sensitivity for right subsegmental branches was 25% and left subsegmental branches was 33.3% (Table 5, Fig. 1).

So, both sensitivity and specificity of noncontrast MRPA in detection of PE in the main pulmonary trunk, right, left main trunk, and lobar divisions were 100%, which was higher than the results obtained by Kalb *et al.* [9], who found that the sensitivity of noncontrast MRPA in detection of PE in lobar branches only was ranging from 40 to 70% varying according to which side and which lobar branch is involved, being 40% only in the lobar branch of the lingula and 70% at the lower lobar branches, postulated the low sensitivity at the lobar branch of the lingula to the vascular geometry in this area, in addition to cardiac and respiratory-motion effects [9].

In the current study, sensitivity results are also higher than the results obtained by Mudge *et al.* [1], who found that the sensitivity of noncontrast MRPA was ranging from 30 to 100%, being 30% at the upper lobar branches and 100% at the lower lobar branches.

Sherif *et al.* [7] found that the sensitivity of noncontrast MRPA was ranging from 50 to 100%, being 50% at the right-lower lobar branches and 100% at the main branches.

Figure 1



A case with left main pulmonary artery embolism appears in MRI (a) and CTPA (b). CTPA, computed tomography pulmonary angiography.

All these studies did not investigate the segmental and subsegmental pulmonary arteries that were involved in this study.

In the current study, the lower results in the segmental and subsegmental branches PE in MRI than CTPA may be explained due to low MRPA resolution due to thick image acquisition, breathing-motion artifacts due to long examination time, and the delay time between noncontrast MRPA imaging and contrast-enhanced computed tomography angiography, within this period, the patient received PE treatment. Image resolution at the segmental branches as well as the close of right lower-lobe segmental branches to the diaphragm, making them more reliable to breathing-motion artifacts.

Hu *et al.* [10] investigated 30 patients with suspected PE who were examined using multislice CTPA and were scheduled for three-dimensional dynamic contrast-enhanced MRPA for the diagnosis of PE. CTPA in detecting pulmonary trunk, interlobar, and segmental artery was greatly accurate. However, in diagnosing, subsegmental and peripheral vessels proved more difficult. Compared with CTPA, MRI allowed for the acquisition of multidimensional images and was superior to CTPA in revealing smaller pulmonary vessel branches, as 26 cases of PE were diagnosed in the CTPA group, with a sensitivity of 90.5% and specificity of 86.7%. Twenty-five cases were diagnosed in the MRI group, with a sensitivity of 92.3% and specificity of 84.2%. In conclusion, three-dimensional dynamic contrast-enhanced MRPA surpassed msCTPA in revealing segmental and subsegmental pulmonary artery PE [10].

This study had some limitations: MRI protocol was not specifically designed for the evaluation of the pulmonary vasculature. An improved MRI protocol, using multiplanar imaging, decreased slice thickness and separation, increased field of view, and increased in-plane resolution, would likely improve the sensitivity for detection of MRI. The study is also limited by the small number of patients. This study was also limited by the timing of the MRI. As MRI was not performed immediately following CTPA, it is possible that by the time of the MRI, the emboli seen on the CTPA had been lysed, particularly given that patients were treated with anticoagulation between the CTPA and

the MRI. An additional potential limitation of MRI for the evaluation of PE is the substantially longer time required for image acquisition. Although in this study all patients were able to complete the MRI, it did take significantly longer than the CTPA (30 min for MRI vs. 2.7 min for CTPA, $P < 0.001$). Given this time difference, it is possible that some acutely ill patients may not be able to tolerate the MRI.

Conclusion

MRI is an emerging new modality in diagnosis of PE with avoidance of exposure to ionizing radiation and contrast agents. MRI has high sensitivity and specificity in diagnosis of PE in the main and lobar branches of the pulmonary artery, MRI has less sensitivity in diagnosing PE in the segmental and subsegmental branches of the pulmonary artery than CTPA.

Financial support and sponsorship

Nil.

Conflicts of interest

Nothing to declare.

References

- Mudge CS, Healey TT, Ataly MK, Pezzullo JA. Feasibility of detecting pulmonary embolism using noncontrast MRI. *ISRN Radiol* 2013; 263:271–278.
- Goldhaber SZ. Pulmonary embolism. *N Engl J Med* 1998; 339:93–104.
- Smith-Bindman R, Lipson J, Marcus R, Kim K-P, Mahesh M, Gould R, de Gonzalez AB, Miglioretti D. Radiation dose associated with common computed tomography examinations and the associated life time attributable risk of cancer. *Arch Intern Med* 2010; 45:321–328.
- Huisman MV, Klok FA. Magnetic resonance imaging for diagnosis of acute pulmonary embolism: not yet a suitable alternative to CT-PA. *1012. J Thromb Haemost* 2012; 10:741–244.
- Ley S, Kreitner KF. Pulmonary hypertension and thromboembolic disease. In: Kauczor HU editor. *MRI of the lung*. 1st ed. Medical Radiology. Berlin; Heidelberg: Springer-Verlag; 2009. doi: 10.1007/978-3-540-34619-7_6
- Kluge A, Mueller C, Strunk J, Lange U, Bachmann G. Experience in 207 combined MRI examinations for acute pulmonary embolism and deep vein thrombosis. *Am J Roentgenol* 2006; 186:1686–1696.
- Sherif IA, Mohamed A, Ahmad LA, Mohamed AO. Role of non-contrast MRI in diagnosis of pulmonary embolism, a Radiology Department, Faculty of medicine, Ain Shams University, Cairo, Egypt. *Egypt J Hosp Med* 2017; 68:1196–1201.
- Sikora-Skrabaka M, Skrabaka D, Ruggeri P, Caramori G, Skoczyński S, Barczyk A. D-dimer value in the diagnosis of pulmonary embolism. *J Thorac Dis* 2019; 11:664–672.
- Kalb B, Sharma P, Tigges S, Ray GL, Kitajima HD, Costello JR, Chen Z, Martin DR. MR imaging of pulmonary embolism: diagnostic accuracy of contrast enhanced 3D MR pulmonary angiography, contrastenhanced low-flip angle 3D GRE, and non-enhanced freeinduction FISP sequences. *Radiology* 2012; 263:320–356.
- Hu J, Li Z, Qu Y, Sun J, Zhang G. Characteristics and clinical value of 3D MR imaging in the diagnosis of pulmonary embolism. *Exp Ther Med* 2016; 12:1760–1764.